



PATIENT

Molly Newson

SPECIES

Canine

BREED

Weimaraner

SEX

Female Spayed

AGE

9 years

WEIGHT

76.1lbs

INTERPRETED BY

Maggie Machen Lamy,
DVM, DACVIM
(Cardiology)

IMAGING PERFORMED BY

C. Belan, DVM

HOSPITAL NAME

Signal Hill Animal
Clinic

REFERRING VET

Dr. Cumyn

INVOICE

29767

DATE

3/22/23

PRESENTING CLINICAL SIGNS

History: Grade 4/6 heart murmur. New arrhythmia. On Acana for last 24 months unsure prior to that. Asymptomatic. Assess prior to anesthesia.

ECHOCARDIOGRAM FINDINGS

2D, m-mode, color flow and doppler imaging is available. The mitral valve appears mildly thickened, with no obvious prolapse into the left atrial lumen. Mild eccentric MR. Mild to moderate left atrial dilation. The LV is dilated in both systole and diastole with increased sphericity. Moderate decline in myocardial function. Normal LV wall thickness. The tricuspid valve appears normal in form and function. Trace TR. Normal TR velocity. Prominent right atrial and ventricular diameter. No overt evidence of pulmonary arterial hypertension or right heart decompensation. The aortic valve is normal in morphology and mobility. No subvalvular ridge present; normal LVOT velocity with laminar flow. No aortic insufficiency. Normal pulmonic valve with no pulmonic insufficiency seen. Normal RVOT velocity. No pericardial or pleural effusion noted. No obvious cardiac tumors.

CARDIAC CHART

CANINE CARDIAC PARAMETERS	MR VMAX (m/s)	TR VMAX (m/s)	LA/AO (Boon method)	LA/AO (Heart Base; Swe)	FS (%)	EF (%)	EPSS (cm)
NORMAL PARAMETER	4.5-5.5	<2.7	1.3	<1.6	28-40	40-100	<0.6
PATIENT	5.0	2.0	1.3	1.6	18	32	0.6
CANINE CARDIAC PARAMETERS	HR (BPM)	AV VMAX (m/s)	PV MAX (m/s)	BODY WEIGHT (kg)	LA 2D short axis Base view (cm)	LVIDd Avg; 2D and m-mode short axis (cm)	LVIDs Avg; 2D and m-mode short axis (cm)
NORMAL PARAMETER	50-100	0.7-1.7	0.7-1.6	BELOW	BELOW	BELOW	BELOW
PATIENT	104	1.4	0.9	34.5	3.1	5.0	4.1
*Normal chamber parameters expressed as a mean value (SD)				3	1.27 (5.3)	2.46 (2.46)	1.36 (5.5)
BODY WEIGHT DEPENDENT PARAMETERS				5	1.40 (4.5)	2.74 (5.2)	1.60 (4.7)
<i>*Note: All measurements based upon multi-modal images and methods. An average value is reported.</i>				10	1.50 (3.8)	3.27 (3.5)	2.06 (3.1)
				15	1.83 (2.0)	3.71 (2.4)	2.43 (2.1)
				20	2.02 (1.9)	4.14 (2.2)	2.80 (2.0)
				25	2.18 (2.4)	4.48 (2.9)	3.10 (2.5)
				30	2.33 (3.3)	4.83 (3.9)	3.39 (3.4)
				35	2.48 (4.3)	5.17 (5.0)	3.69 (4.5)
				40	2.62 (5.2)	5.48 (6.1)	3.96 (5.4)
				50	2.88 (7.1)	6.07 (8.3)	4.46 (7.4)

INTERPRETATION OF THE FINDINGS & FURTHER RECOMMENDATIONS

Significant left heart dilation with a decline in systolic function is identified. Mild MR is noted as the cause of the murmur, which likely reflects current valve disease. The LA is moderately enlarged as well however, indicating a concern for progression in the future. No additional issues are identified in this study.



PATIENT

Molly Newson

SPECIES

Canine

BREED

Weimaraner

SEX

Female Spayed

AGE

9 years

WEIGHT

76.1lbs

INTERPRETED BY

Maggie Machen Lamy,
DVM, DACVIM
(Cardiology)

IMAGING PERFORMED BY

C. Belan, DVM

HOSPITAL NAME

Signal Hill Animal
Clinic

REFERRING VET

Dr. Cumyn

INVOICE

29767

DATE

3/22/23

Dilation and dysfunction can be primary in nature (early primary DCM) or develop secondary to taurine deficiency, myocarditis, hypothyroidism, tachycardia-induced cardiomyopathy, or infiltrative disease such as lymphoma. Given the diet history, there is great concern for correlation with a grain free diet being fed in light of recent reports. An immediate diet change is recommended in addition to supplementing Taurine as below. Consider screening for additional causes such as submitting a thyroid panel.

Prognosis is guarded at this stage, as rate of progression will dictate true clinical implication of today's findings long term. There may be risk for development of congestive heart failure, malignant arrhythmias (AF, VT), collapse and/or sudden death in the future. **An arrhythmia is noted in the history and an ECG is strongly recommended.**

Once on the medication for 3-5 days, anesthetic risk is considered moderately elevated. A screening BP is recommended prior to induction. Cardiac protective drug choices (opioid/benzodiazepine premedication, Propofol or alfaxalone induction, iso/sevo gas) are recommended. Monitor for arrhythmias, hypotension, and hypoxia both intra and post-operatively and intervene as necessary. Judicious IV fluid rates are recommended to avoid fluid overload. Avoid heart rate stimulating drugs, alpha 2 agonists, telazol unless clinically necessary.

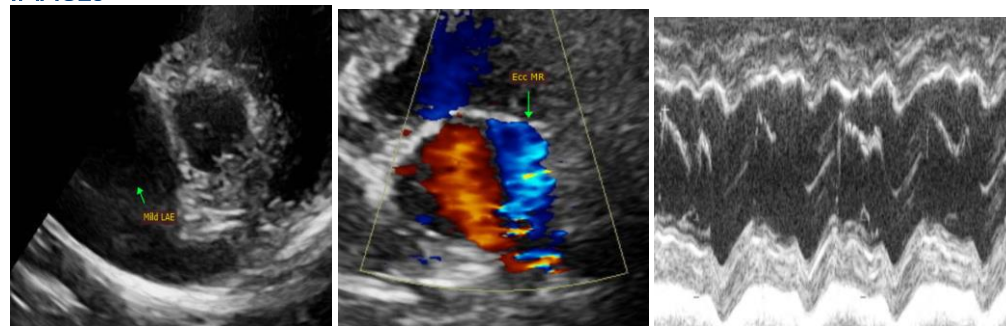
Monitor for development of a progressive murmur, cough, labored breathing, exercise intolerance or collapse episodes.

PLAN

Diet change recommended. Institute Pimobendan (0.25-0.3mg/kg PO q12h). Supplement taurine, 1000-2000mg PO q12h. Baseline BP and ECG are recommended. Consider a thyroid level if not recently assessed.

A recheck echocardiogram is recommended in 6 months, sooner if a murmur develops or any signs of cardiac disease are noted.

IMAGES



The information and recommendations provided are based on the images presented by the referring veterinarian. No evaluation can be communicated regarding pathology that was not visible in the image/video clips provided.

Thank you for this referral. This report was generated using transcription software, and minor dictation errors may be present. If the clinical or image interpretation does not parallel your findings or if I can be of any further assistance, please contact me.



PATIENT

Molly Newson

Maggie Machen Lamy, DVM
Diplomate of the American College of Veterinary Internal Medicine (Cardiology)
info@sonopath.com

SPECIES

Canine

BREED

Weimaraner

SEX

Female Spayed

AGE

9 years

WEIGHT

76.1lbs

INTERPRETED BY

Maggie Machen Lamy,
DVM, DACVIM
(Cardiology)

**IMAGING
PERFORMED BY**

C. Belan, DVM

HOSPITAL NAME

Signal Hill Animal
Clinic

REFERRING VET

Dr. Cumyn

INVOICE

29767

DATE

3/22/23